

WE HOLD THESE TRUTHS TO BE SELF-EVIDENT

I hope my American friends will forgive me for borrowing that snippet from their Declaration of Independence. Many years ago I did a piece trying to dispel some of the commonly-held misconceptions about veterinary dentistry (www.toothvet.ca/PDFfiles/mythology.pdf). I would now like to take some time to reveal some facts and trends that we in the veterinary dental community are very aware of but that still may not be commonly known to the general practitioner.

Dachshunds have oronasal fistulae until proven otherwise

Some years ago at the Veterinary Dental Forum, there was coincidentally a rally of dachshund owners and their dogs. As the little dogs trotted past during their costume parade, one of our group announced “Oh look. The Fistul Futurity”. We all knew exactly what she meant because it is well known among veterinary dentists that every dachshund either has oronasal fistulae or is just about to get them.

Deep periodontal pockets on the palatal side of the upper canine teeth are so common in this breed and these pocket so often erode right through into the nasal passage that we assume all dachshunds have oronasal fistulae until proven otherwise.

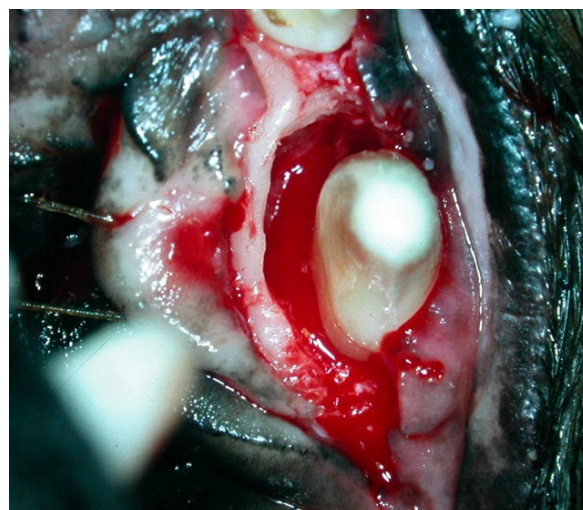
While we (veterinary dentists) know this to be the case I was recently reminded that not all GPs do. I have seen more than one dachshund who has had incredibly involved and expensive work-ups and treatments for chronic upper respiratory disease but without anyone ever assessing the periodontal status of the upper canine teeth. Invariably, when I see the animal, I find an oronasal fistula (or two), deal with it and the chronic upper respiratory complaints disappear.

What should you do about this? If you have a client with a young dachshund, you can be proactive. Explain to the owners that their dog is of a breed very prone to serious periodontal disease affecting the upper canine teeth and that adopting an aggressive preventative program can

pay big dividends. If the patient is really young (6 months or so), and has no dental concerns (all primary teeth gone, all adult teeth erupted into proper positions...) then the owners should start working on a home care program, training the dog to enjoy having its teeth brushed daily. Extra effort should be made to brush the palatal side of those upper canine teeth. Then, no matter how successful the owners are with the brushing, plan on anesthetizing the patient on an annual basis to clean below the gum line where the brush cannot reach.

For the more mature dachshund who is not yet showing any respiratory signs, even if the crowns of the teeth look perfectly normal, plan to anesthetize to probe and explore around all the teeth and clean them above and below the gum line. Then get the owners working on the home care program and set up the annual recall schedule.

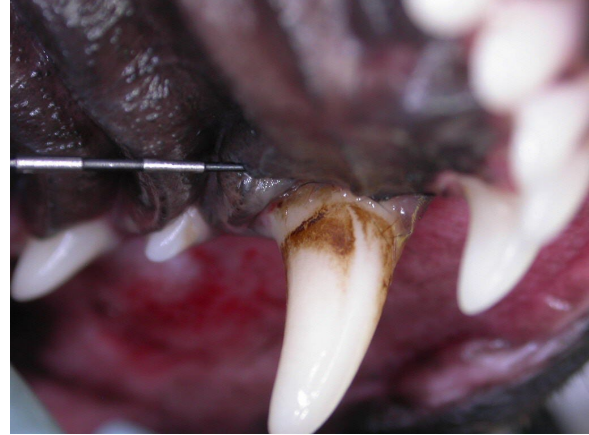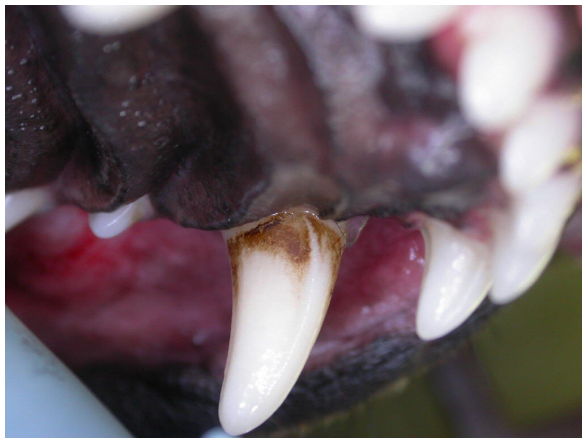For any dachshund showing any upper respiratory signs, put oronasal fistula as the first rule out and investigate that before doing anything else. Fine, you can run some pre-anesthetic blood work first but then the very next step is to anesthetize to probe and explore around all of the maxillary teeth and get intra-oral dental and nasal radiographs.



Above is an intra-operative view of a large infra-bony pocket on the palatal side of the right maxillary canine tooth. The palatal mucosa has been elevated and retracted to the left. The root surface has been cleaned and the inflamed soft

tissue removed from the pocket. If during these surgical manipulations any epistaxis had been noted, that would have meant there was already a fistula and I would have proceeded to extract the tooth and suture the wound.

The following two photos are from a four-year old Dachshund who was presented for treatment of a fractured fourth premolar. A casual glance suggested that he had excellent oral hygiene and periodontal health. However, a look at the palatal side of the left upper canine revealed more accumulation of supra gingival deposits there than elsewhere in the mouth. This is a hard area to photograph well, but on reflecting the palatal gingiva (second photo) I could see considerable calculus accumulation subgingivally. Probing depths for both upper canines on the palatal side were 6 millimeters. In a dog this size I would accept probing depths of 2, maybe 3 millimeters as normal so this young dog had already started to develop significant periodontal pockets. I did root planing and subgingival curettage to remove the plaque and calculus from the root surface and inflamed soft tissue from the pocket wall. Now we need to get the owners brushing this area daily to keep it clean and we re-assess, under anesthetic, in one year no matter how clean the crowns may look. Clean crowns mean nothing if there is trouble below the gum line and so that is what we must evaluate and treat.



This dachshund's upper canines now have a chance because the problem was found relatively early in its development, has been treated and pointed out to the owners and hopefully an effective management program has been put in place.

Dachshunds are not the only dogs afflicted with deep periodontal pockets on the palatal side of their maxillary canines. Any dog with these teeth is a potential candidate. Others that I would say are at higher-than-average risk are any really little dogs (micro-dogs) as well as basset hounds.

It is also not only the maxillary canine teeth that can give rise to oronasal fistulae. Periodontal or endodontic disease at any of the maxillary premolars can also result in fistulation into the nasal passage.

The 'take-home' messages here are:

- Dachshunds get oronasal fistulae at their upper canine teeth
- Any dog (or cat) with chronic rhinitis or upper airway disease should have a detailed oral/dental examination with radiographs and probing to find or rule out an oronasal fistula as the cause.

Pulp Exposure means endodontic therapy or extraction. There are no other options.

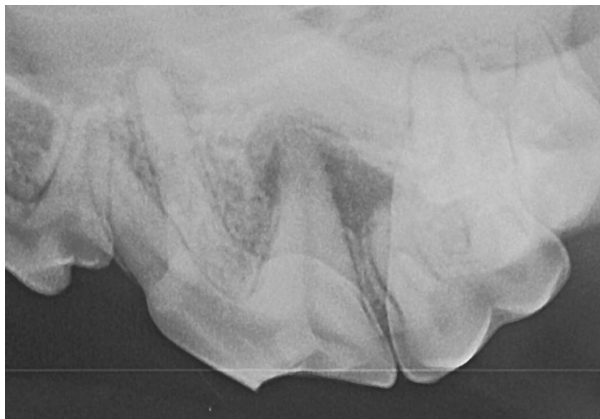
Before proceeding, please review this paper:
<http://www.toothvet.ca/PDFfiles/endo.pdf>

Based on that, you can see that if the crown of a tooth is fractured in a way that exposes the pulp, you can be completely certain that the tooth

needs either extraction or endodontic therapy. Left untreated it is completely inevitable that the pulp will undergo septic necrosis and then the tooth is a hollow tube, full of bacteria embedded in the jaw bone. It is an open wound that the body has no way of closing. Chronic periapical infection and inflammation will always follow.

Teeth with crown fractures and pulp exposure cannot be managed with medications and should not be subject to wait-and-see. If the pulp is exposed, the only options are extraction or endodontic therapy.

Delay does the patient no good and can do it harm. The radiograph that follows happens to be from the same four-year-old dachshund referred to in the last bit and this is the pre-operative radiograph of the left caudal maxilla. The crown fracture of the four premolar tooth led to septic pulp necrosis, periapical periodontitis, eventual fenestration of infection through the alveolar bone over the distal root allowing the infection into the infra-orbital soft tissue resulting in an infra-orbital cellulitis/facial swelling. When this was first presented to the referring veterinarian the owner was not 'ready' to proceed with extraction and so the dog was given a course of antibiotics. When I saw the dog 3.5 months later the radiograph showed that the periapical lesion had grown large enough to encompass the mesial root of the first molar. Therefore, not only did the fourth premolar have to go, so did the first molar. Since I have no radiograph from the first episode of facial swelling, I cannot know that things would have been any different then, but it is certainly possible that the molar might have been fine if we had been able to do surgery the first time the face blew up.



Antibiotics do nothing to deal with the portal of entry for the bacteria or to clear out the reservoir of bacteria inside the dead tooth. If the tooth is recently fractured and the pulp is alive, antibiotics will not keep the pulp alive and will have no effect on the progression of the disease or on the outcome of the treatment. In short, antibiotics are not indicated in the treatment of a fractured tooth unless the problem has resulted in an acute facial cellulitis. In that case, some antibiotics to calm down the infection in the soft tissue surrounding the tooth would be fine for the few days before the patient can be scheduled for surgery. Antibiotics are not a substitute for definitive surgical treatment.

Chipped or abraded teeth with dentin exposure are in a grey zone with some surviving and some developing septic pulp necrosis. They require careful clinical and radiographic evaluation to develop a treatment plan. More on that can be learned here:

www.toothvet.ca/PDFfiles/endo_dx.pdf

Fractured Teeth in young animals need immediate treatment if we are going to save the tooth

For back ground on this subject, you should have a look at the following paper:

<http://www.toothvet.ca/PDFfiles/Pulpotomy.pdf>

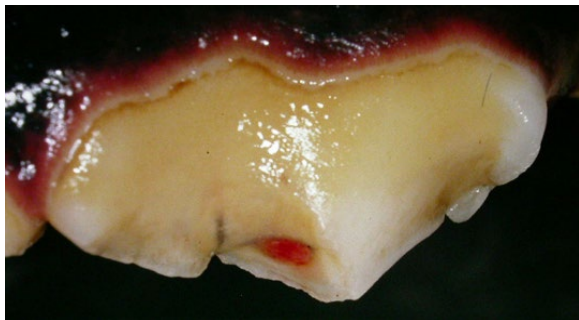
We are mostly talking about canine teeth in this discussion. If a dog or cat under a year (or two) of age suffers a fracture of one of its canine teeth and there is pulp exposure, we have (as stated above) only two options – endodontic treatment or extraction. In this case, however, since the pulp chamber is still large and the dentin wall of the tooth thin, there is a great incentive for maintaining the vitality of the pulp. This would allow the pulp to continue its important task of producing dentin inside the tooth so the tooth can continue to grow stronger. Also, a tooth with live pulp inside is more resilient (flexible, less prone to fracture) than a tooth that has dead pulp or has had total pulpectomy.

In order to maintain the vitality of the pulp in a recently fractured tooth in a young animal, the tooth needs vital pulp therapy before oral bacteria have a chance to penetrate deep into the pulp tissue – hence the need for speed.

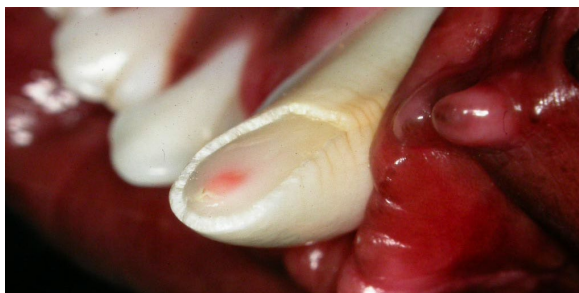Preferably, these teeth will receive partial vital pulpotomy, direct pulp capping and bonded composite restorations within 24 hours of the injury. The younger the patient, the larger and more resilient the pulp is so slightly longer delay may be tolerated. I am *generally* comfortable offering vital pulp therapy up to 72 hours post injury in animals under 18 months of age, but after that, the prognosis really starts to go down hill with each passing day.

If you are a referring veterinarian and a client calls to say their young pet has just suffered a crown fracture and they can see the pulp, do not delay referral by asking to see the animal yourself before calling the dentist of your choice – set up the referral immediately.

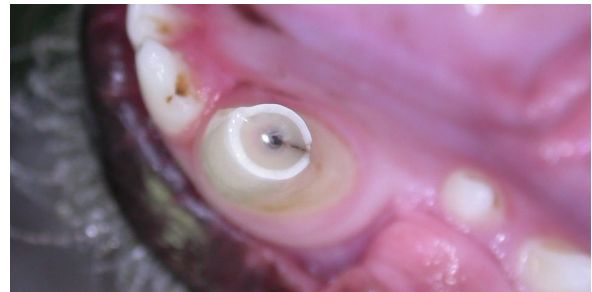If you are an animal owner and your pet has suffered a crown fracture and you can see the pulp tissue, ask your veterinarian for the name and number of a qualified veterinary dentist so you can call them right away. The photo that follows shows a fractured right upper fourth premolar tooth with exposed, pink, live pulp tissue.



The next photo shows a lower left canine tooth with a fracture that is so close to the pulp that you can see the pulp through the thin layer of remaining dentin. This young tooth also needed immediate vital pulp therapy to keep it alive.



And this next photo shows a lower left canine tooth for which vital pulp therapy is most definitely not an option as the pulp tissue is already dead.



Dental Disease is a Surgical problem, not a medical one

Time and again we see histories in which dental disease has been detected and the first course of action was to prescribe antibiotics or an antiseptic oral rinse. This is putting the cart before the horse (and it is the wrong cart for this horse).

While periodontal disease and gingivitis are the result of the actions of pathogenic bacteria (and the animal's response to them), this is not an infection that can be managed with antibiotics or antiseptic agents. The bacteria that are involved in gingivitis and periodontitis live in a structure known as dental plaque. Plaque is a biofilm which is to say it is a complex structure/society composed of dozens to hundreds of species of micro-organism all living within a protective slime that they produce and excrete.

For more on the structure and biology of dental plaque, here are a few pages I found with a quick Google® search:

<http://www.dentistry.leeds.ac.uk/OROFACE/PAGES/micro/micro2.html>

<http://www.dent.ucla.edu/pic/members/microbio/mdphome.html>

Both of those web pages are discussing plaque in human mouths and so there are some differences in the specifics of the bacteria found there compared to what is found in a dog or cat mouth. Regardless, the principles of plaque development and biology/structure do cross species.

The biofilm resides on the surface of the hard dental structures and within the pores of any

mineral deposits (calculus, tartar) on these surfaces (crowns, roots). There is no blood flow that reaches the biofilm. Therefore giving systemic antibiotics, even if they had a spectrum that would target the vast variety of bacteria in the biofilm will not get where the bacteria are living and so will have no effect on them. Systemic antibiotics may help reduce the bacteria count in the surrounding soft tissues and so may make them look better for a time but they will have no effect on the source of the problem.

Even if we could get the antibiotics to the surface of the biofilm, its structure and ecology affords many protections to the bacteria within. Bacteria in a biofilm are reported to be up to 1500 times more resistant to antimicrobial agents than bacteria in a monoculture. A good review of this can be found at:

http://books.google.ca/books?id=MbtCOHwAilQC&pg=PA57&lpg=PA56&ots=X5o2l_Vfx8&dq=bacterial+resistance+in+biofilm#PPA56,M1

This paper discusses biofilms as they occur in a number of environments including industrial installations as well as on medical implants (catheters, prosthetic joints, heart valves...). Regardless of the location, the principles apply – bacteria in an undisturbed biofilm are very hard to kill.

As well as antibiotics, many people will try antiseptic rinses of one sort or another. While some oral antiseptic can be a useful tool as part of an oral care program none are really of much value as a simple rinse. When we (human patients) use an oral antiseptic, we are instructed to swish/rinse/gargle for 30 to 60 seconds as contact time is important for the agent to have any effect. Dogs and cats do not swish and gargle – they swallow right away and so contact time is insufficient to allow the agent to do anything. Also, when we (human patients) use a rinse or mouthwash, we combine this with mechanical plaque removal in the form of flossing and brushing. Simply rinsing with a mouth wash may make the breath less offensive, but there is no real therapeutic effect.

With most endodontic disease, the pulp chamber of the tooth is filled with necrotic pulp debris and bacteria. The bacteria and their toxins ooze out through the tip of the root to cause infection

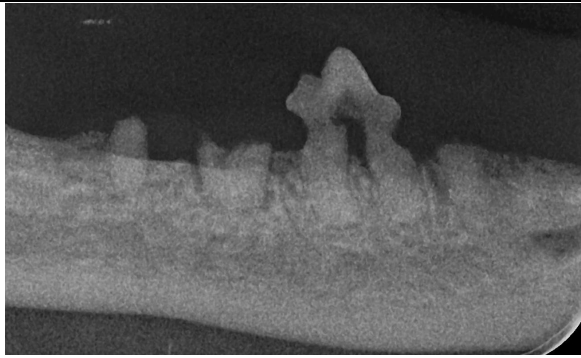
in the tissues around the root tip (periapical periodontitis), but since there is no live tissue inside the tooth, systemic antibiotic do not get into the pulp chamber and so again, can have no effect on the source of the infection.

When a tooth is fractured and the pulp chamber exposed to oral bacteria the tooth effectively becomes a hollow tube embedded in bone into which the animal is spitting on a constant basis. If you had a surgical-grade stainless steel tube embedded through your thigh into your femur and you spat into it several times a day, would antibiotics be of any value in managing the osteomyelitis that would develop? Of course not. Treatment would depend on removing the portal of entry for the bacteria. You would either remove the steel tube (extraction) or sterilizes its interior and seal the opening (root canal treatment).

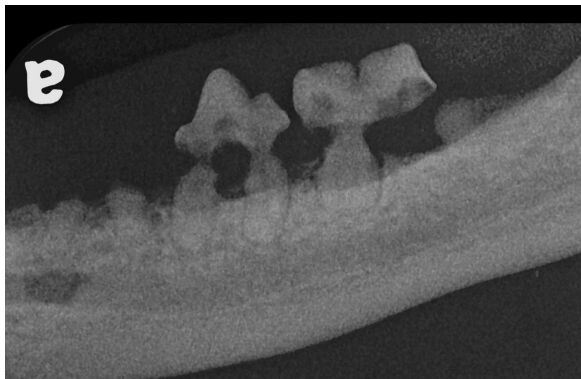
So, when a patient is diagnosed as having dental disease, the first step is to get an accurate assessment of that condition. This involves general anesthesia to allow for a complete and detailed clinical examination with a whole-mouth radiographic survey. Once a diagnosis has been established, an appropriate treatment plan can be developed, in consultation with the owner. This is the basis of the COHAT (comprehensive oral health assessment and treatment).

Post-operatively it may be appropriate to dispense some antibiotics or an oral rinse for the short term, but in most cases, once the source of the infection has been removed through effective oral surgery, the body takes care of the rest with no pharmaceutical assistance.

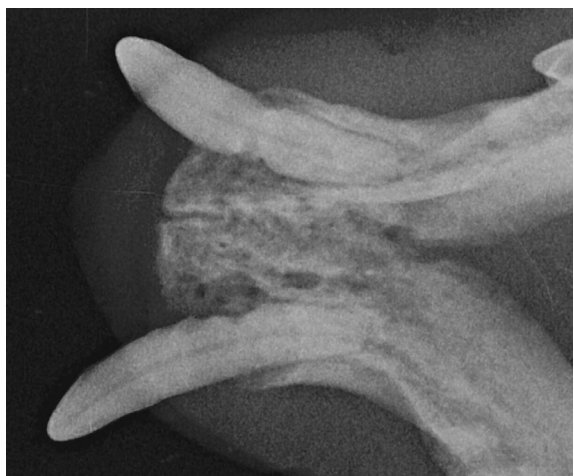As an illustration of how medicating before a COHAT is going to be less than helpful, here are some pre-operative radiographs of a cat that had been treated with various antibiotics, steroids and dental diets. Not surprisingly, none of these helped.



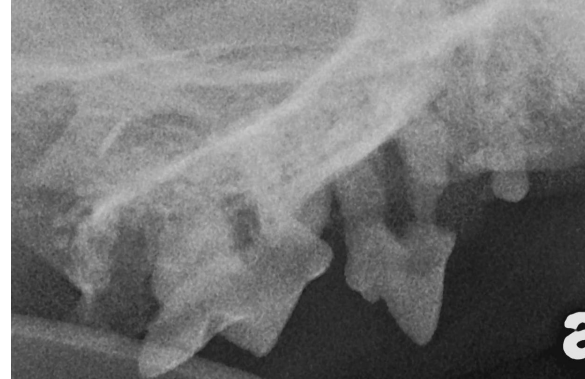Right mandible with crowns of the third premolar and molar gone but roots retained. The fourth premolar has advanced periodontal disease and tooth resorption.



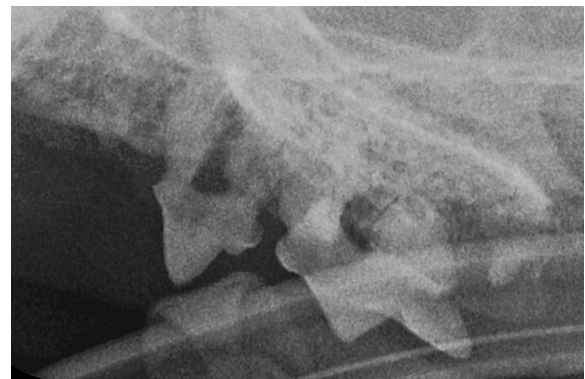
The left mandible. The crown of the third premolar has broken off but the roots remain. The distal root of the molar has been severed by tooth resorption. The fourth premolar and molar both have advanced periodontal disease as well as tooth resorption.



The lower canine teeth both have deep periodontal pockets with tooth resorption on the root surfaces within these pockets.



The right maxilla showing a small remnant of the molar still in place as well as advanced periodontal disease and tooth resorption of the third premolar. More subtle lesions on the fourth premolar were easily detected clinically.



The left maxilla showing a small remnant of the molar, periodontal disease and resorptive lesions of the third and fourth premolars and small retained remnant of the second premolar.

The cat obviously needed whole-mouth extraction (and that is what I did). Antibiotics, steroids, rinses, dental diets, water additives all would have been of no benefit to the patient and could have caused harm. As the heading for this sections says, dental disease is a surgical problem not a medical one.

Home Care is for Prevention, not Treatment.

Along the same lines, while tooth brushing, appropriate dental treats and diets (see www.vohc.org) can be of great value in maintaining good oral health and preventing periodontal disease, they are NOT intended for or appropriate as treatments for established dental disease. In fact, if the patient has dental disease of any sort (periodontal disease,

endodontic disease, tooth resorption...), not only will home-care activities and products be useless, they may also cause considerable pain. Looking back at the cat we just discussed, asking this poor fellow to eat a dental diet is plain wrong. Until all these diseased and painful teeth have been removed, he would be happiest on canned food or tiny kibbles that require no chewing. And can you imagine how it would have felt if someone had tried to brush this cat's teeth? Ouch!

So, if your patient has dental disease it needs a COHAT first. Only after the mouth is known to be healthy and comfortable should home care strategies be brought to bear to help keep it that way.