

DENTAL CARIES

We used to think that dogs did not get cavities. Now we know differently.

In an article published in the Journal of Veterinary Dentistry (15(2), 1998) I pointed out that caries (the proper latin term for bacterial decay of dental hard tissues) does in fact occur in dogs. I also noted that early detection of lesions, or anatomic defects predisposed to the development of lesion allows for restorative procedures to prevent serious decay and loss of the tooth.

Since publishing that article, I have been looking for caries more aggressively and am finding them more often than suggested in the published data. Is the incidence of caries on the rise or am I just finding more of them because I am looking for them? I do not know, but I do know that they occur and we should all be on the look out for them when ever we get a chance. Below is a reprint of the chapter from my book, *Understanding Veterinary Dentistry*, on the subject.

“Cavities” is the common term for dental decay, more properly know as *caries*, which is Latin for rottenness. Caries is one of the most common diseases in man. Caries has been defined as “*a disease of the calcified tissues of the teeth resulting from the action of micro-organisms on carbohydrates, characterized by decalcification of the inorganic portions of the tooth and accompanied or followed by disintegration of the organic portion*”.

Caries then, is a bacterial decay of the tooth structure brought about by the release of acids from oral bacteria fermenting carbohydrates on the tooth surface. Therefore, a diet high in highly refined and easily digestible carbohydrates will favor the development of caries. As western civilization progressed, our diet changed to include the types of foods that would promote decay and so caries became a widespread and serious concern. It is only recently that the use of fluoride and improved oral hygiene practices has brought about a decline in the incidence of caries.

Many owners are unaware that dogs are subject to caries. Though the incidence of caries in dogs is much lower than in humans, it can and does occur and we must watch for areas at risk and recommend such preventive treatments as are reasonable. In a review of my own records (published in the Journal of Veterinary Dentistry, Vol. 15, #2), I found that 5.25% of my adult canine patients had one or more caries lesion.

There must be several factors in place for caries to develop. They include:

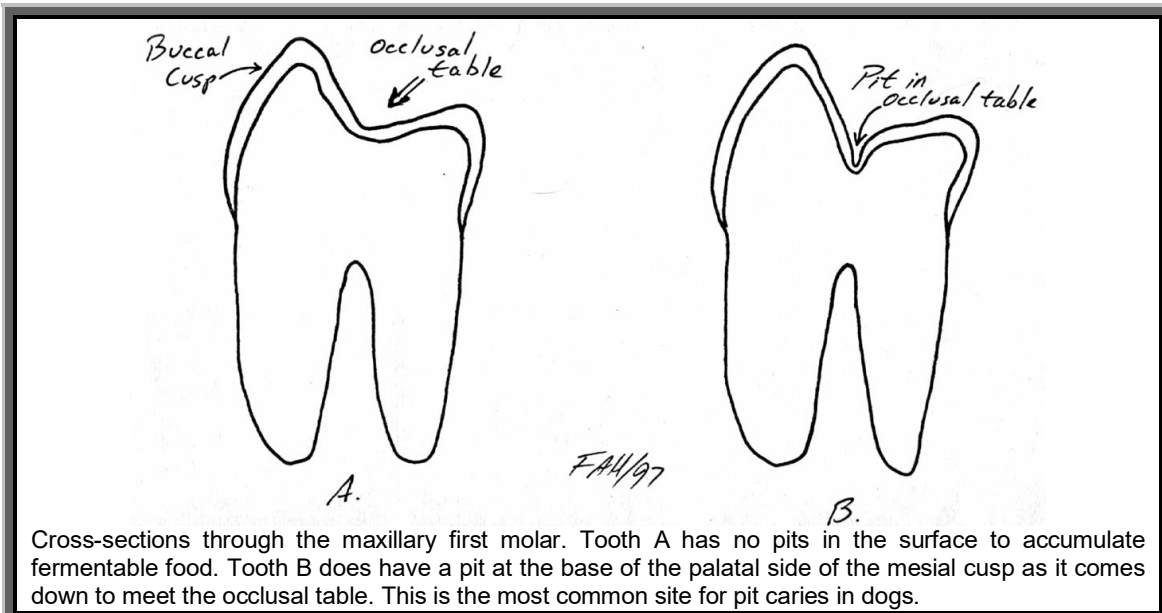
- natural tooth structure with susceptible surface exposed to the oral environment
- complex indigenous microflora
- food ingested by mouth

There are many modifying factors as well, which influence the location of the lesion.

Among the reasons proposed for the lower incidence of caries in dogs are:

- conical tooth shape with less area for food impaction and stagnation
- diets which include little fermentable carbohydrate
- salivary pH is higher (in dogs, mean pH of 7.5 compared to 6.5 in humans) to buffer bacterial acids
- in dogs, a relatively low level of salivary amylase to breakdown starches which are retained in and around the teeth

As bacteria on the tooth surface ferment the carbohydrates, acids (lactic, acetic, propionic) are released. These acids diffuse into and demineralize the surface enamel. Loss of mineral exposes the organic (protein) matrix of the enamel, which is digested by enzymes from the oral bacteria and/or leukocytes. As the process penetrates deeper, microcavitations develop under the surface. As these expand, they coalesce and the undermined enamel collapses.



There is a constant exchange of minerals between the enamel and the oral fluid. If this exchange is balanced, no lesion develops, but if there is a net loss of mineral from the enamel, caries develops. In the very early stages, before the protein matrix collapses, the process can be reversed and the lesion can 'heal'. Once the protein matrix collapses, the lesion is irreversible and treatment is aimed at preventing further progression.

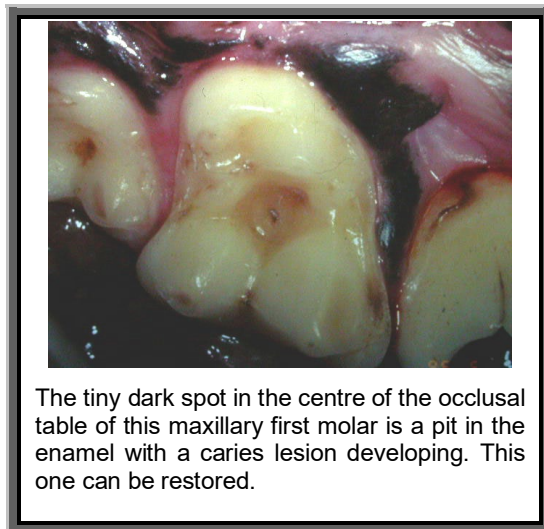
The rate of progression of caries depends more on factors external to the tooth such as the cariogenicity of microflora, the availability of acidogenic substrates and the remineralizing capability of oral fluids. Intrinsic factors include the degree of tissue mineralization and the amount of matrix protein.

Caries can be classified by location as pit and fissure caries, smooth surface caries or root surface caries.

In my experience, pit and fissure caries are the most common type in dogs. They can occur in the pits sometimes found on the occlusal tables the maxillary molars. As Figure #20.1 shows, some teeth have a smooth transition from the palatal wall of the buccal cusps down on to the occlusal table. In other teeth, there is a pit at the base

of the cusps and in these teeth, the enamel is thinner at the bottom of the pit. If food high in carbohydrates becomes trapped in this pit along with sufficient bacteria, a caries is very likely to develop.

Other locations at risk are the deep developmental grooves on the buccal surface of the maxillary fourth premolars and on the lingual side of the mandibular first molars between the mesial and central cusps. These grooves are often filled with calculus, but on deeper exploration, there may be soft, carious dentin at the base.



The series of diagrams at the bottom of the page shows the progression of a pit caries. Initially, food becomes trapped in an occlusal pit. As the bacteria ferment the carbohydrates, acids diffuse into the enamel and start to remove minerals from the surface. The food packed in the pit prevents oral fluids from reaching the demineralized surface and so remineralization is not possible.

In time, the enamel is completely demineralized and the protein matrix digested. Now the caries has reached the dentin, which has a lower mineral content and a higher protein content. The decay progresses more rapidly in the dentin. Though the entrance to the lesions is the same size, the caries grows larger, undermining the overlying enamel.

Only when the caries is quite large does the overlying enamel cave in at which point the large caries becomes readily detectable. Unfortunately, by the time the lesion is large enough to be easily seen, it has usually extended into the endodontic system of the tooth and there is such extensive loss of tooth structure that extraction is the only option.

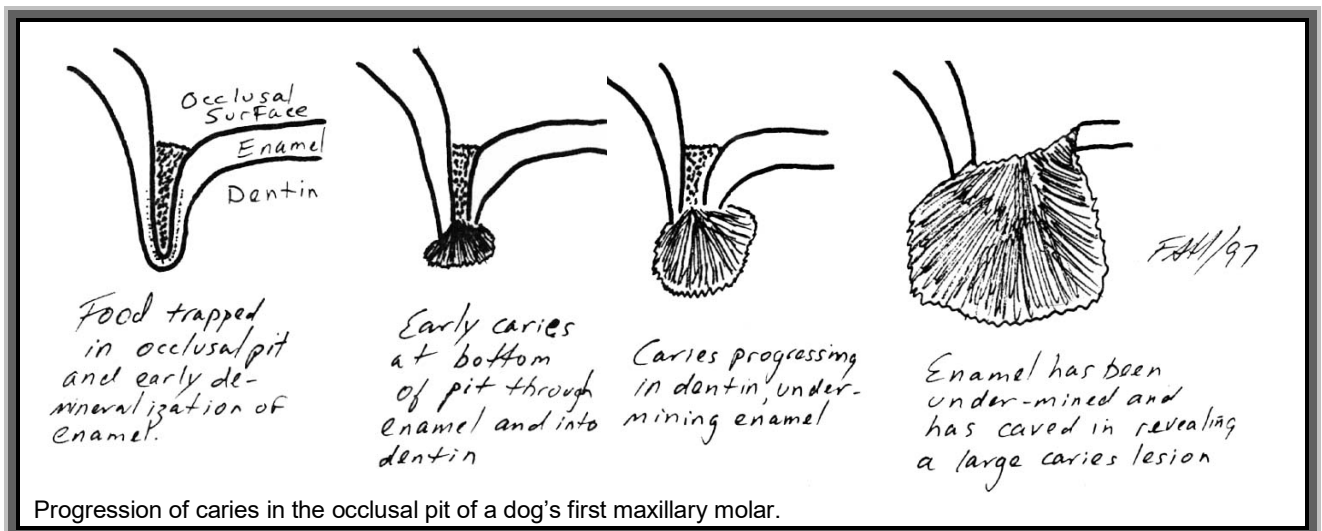
For teeth with deep occlusal pits in young animals that have not started to develop caries, the application of a Pit and Fissure Sealant is an effective preventive treatment.

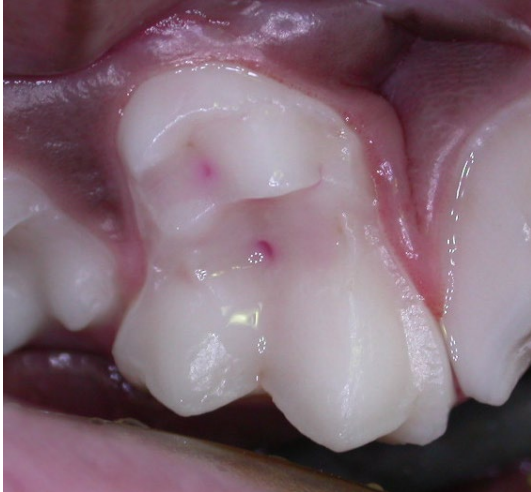For established caries, the decayed enamel and dentin and all debris are removed from the lesion. Endodontic therapy is performed if needed and then the prepared cavity is filled with a dental restorative of some type.

Whenever performing an oral exam or hygiene procedure, be on the look out for small caries lesions that are still treatable as well as areas that might be particularly prone to caries development.

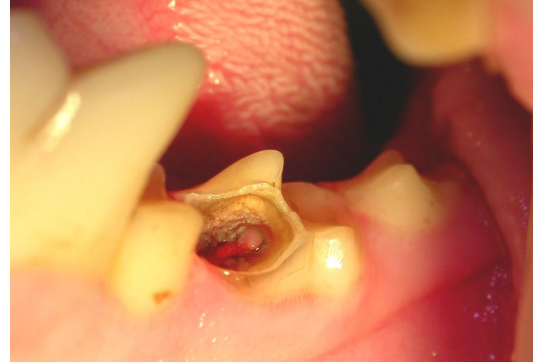In examining the teeth with your dental explorer, check for pits and fissures. If a caries has started to develop, you will be able to force the tip of the explorer into the decaying surface. As you withdraw the instrument, the tip will stick and then let go, resulting in a metallic “ping” from the explorer tip. Sound enamel and dentin are too hard to allow the explorer to penetrate so if you can get your instrument to sink in at all, you have found a caries lesion.

More advanced caries are usually filled with a foul smelling, soft material the consistency of cottage cheese. Under this is decaying dentin, which is softer than sound dentin. Under that, hopefully, will be some sound dentin covering the pulp of the tooth and upon which a restorative can be placed.

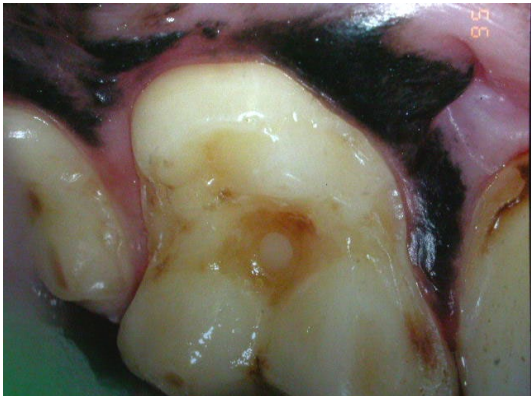



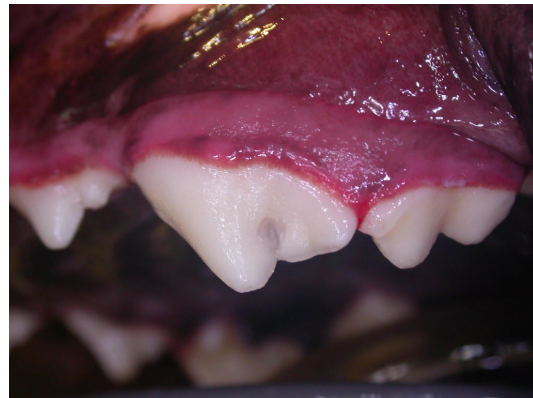
Some deep pits in a young dog's molar highlighted with a pink liquid. These pits had not yet developed any decay and were excellent candidates for prophylactic restorative work (Pit & Fissure Sealant).



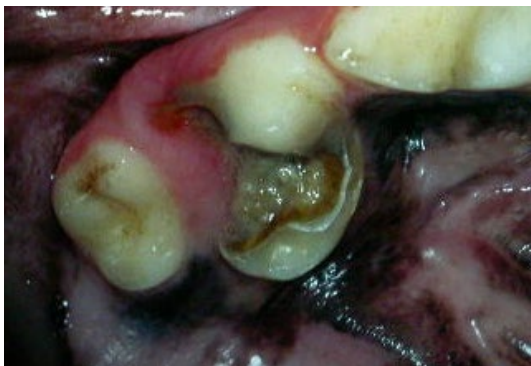If there is a caries in the maxillary first molar, the decay there often spreads to the occluding surface of the mandibular second molar as in this dog. The pink area in the centre of the defect is exposed dental pulp.



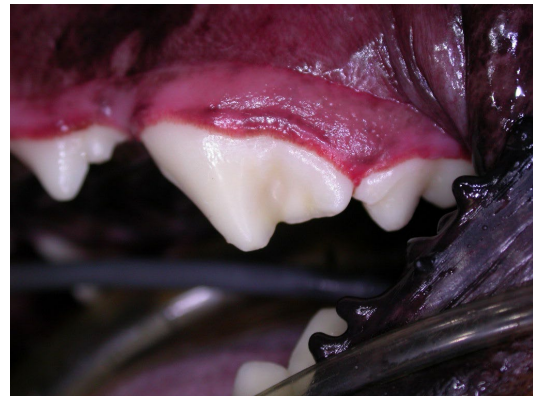The molar from page 2 with its composite restoration in place.



The developmental groove of the maxillary fourth premolar is also a site at risk. This one has been prepared for restoration by removing all the softened dentin and unsupported enamel



It is too late for this advanced caries. Extraction is the only option.



And here it is with its composite restoration.